


Adenocarcinoma in situ of cervix – case report

Dr K. S. Chan
Department of
Obs. & Gynae.


Dr Dorothy Law
Department of
Pathology

Kwong Wah Hospital



Presentation

- ✦ Name: LSL
- ✦ Age: 66
- ✦ Age of Menopause: 53
- ✦ Past Obstetric History:
 - ▣ 6 FTNSD
- ✦ Past Gynaecological History:
 - ▣ Unremarkable, no previous cervical smear (?)



Presentation

⊕ Past Medical History:


- ⊞ Hypertension on medication for 20 years
- ⊞ Mild DM for 2 years, on diet only

⊕ Social History:

- ⊞ Housewife, married at 23 years old
- ⊞ Non-smoker, non-drinker

⊕ Family History:

- ⊞ Unremarkable




Presentation

⊕ Symptoms:

- ⊞ Recurrent postmenopausal vaginal bleeding since two years ago
- ⊞ Attended OLMH in March 2000

⊞ Investigations:

- Cervical smear (22-3-2000): suspected endocervical adenocarcinoma-in-situ
- Hysteroscopy & uterine curettage (22-3-2000):
 - Atrophic endometrium, scanty curettings yielded



Colposcopic findings

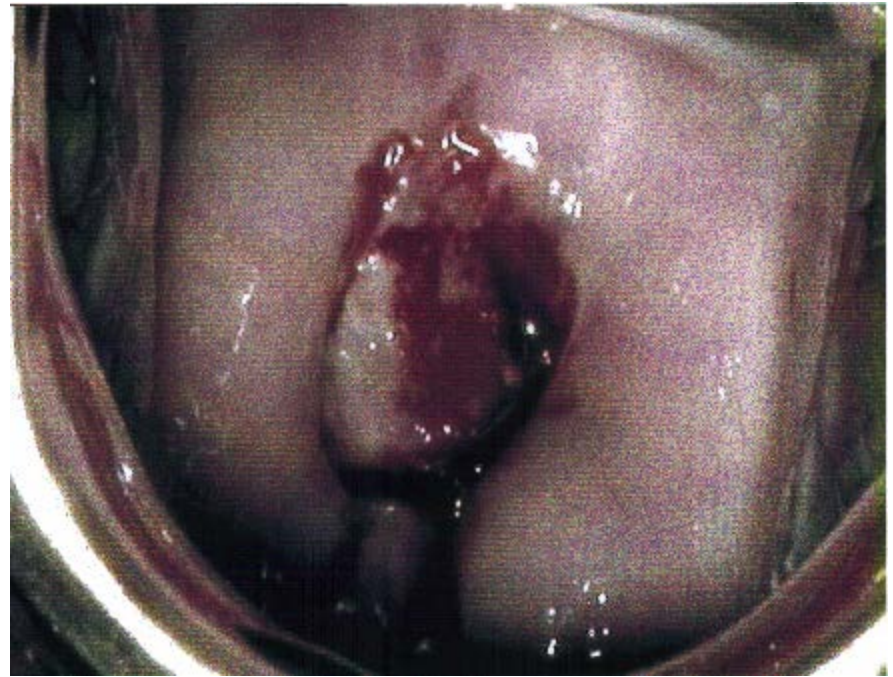
✦ 13-4-2000:


✦ Colposcopy examination
in KWH

- Polypoid growth with acetowhite inside anterior lip of endocervix
- Ectocervix:
 - Normal
 - No punctation, no mosaicism
 - No atypical vessels

✦ Vaginal and rectal
examination:

- Uterus: small
- Parametrium: free





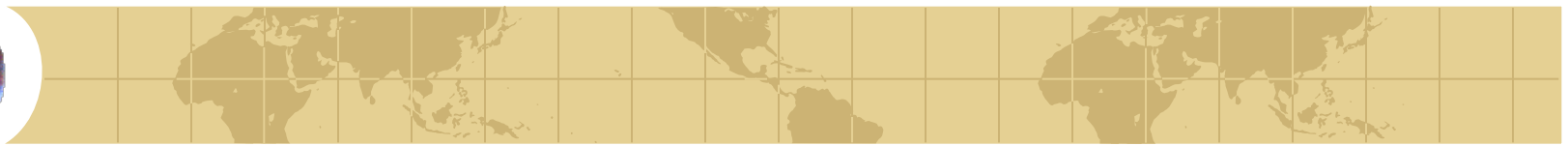
Management

✚ 13-4-2000:

- ✚ Cervical biopsy: adenocarcinoma-in-situ
- ✚ Endocervical curettage: A.I.S.

✚ 28-4-2000:

- ✚ Large loop excision of transformation zone
- ✚ Histology:
 - adenocarcinoma-in-situ at 10-12 & 2-5 o'clock, endocervical margin involved




Management

✚ 22-6-2000:

▣ Total abdominal hysterectomy plus bilateral salpingo-oophorectomy

▣ Histology:


- Adenocarcinoma-in-situ
- Distal margin involved
- Radial margin: free from disease



Follow-up

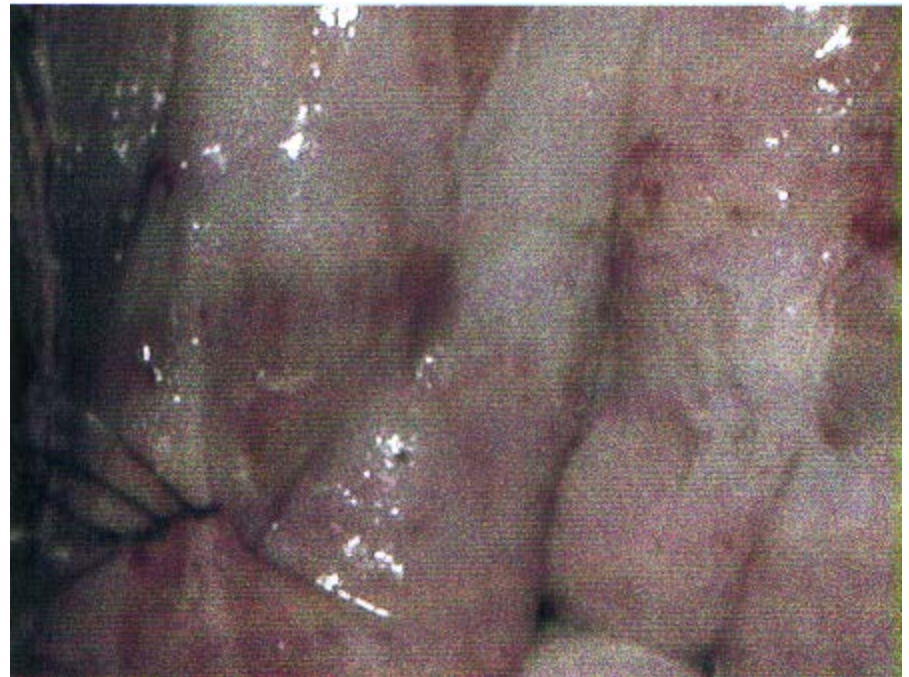✦ Vault smear:


- ❑ 20-9-2000: ASCUS
- ❑ 20-9-2000: Normal
- ❑ 18-4-2001: Adenocinoma, favour endocervical origin
- ❑ 09-5-2001: Adenocinoma



Colposcopic findings

- ⊕ 19-5-2001:
 - ⊗ Vaginal and rectal examination:
 - unremarkable
 - ⊗ Colposcopic examination:
 - Dense acetowhite lesion at vaginal vault, esp. left side
 - No growth seen
 - No punctation, no mosaicism, no atypical vessel
- ⊕ Histology of Vaginal vault biopsy:
 - ⊗ VAIN I, condyloma





Management

✚ 1-6-2001:

- ▣ Vault stripping


- ▣ Histology: Condyloma only

✚ Other investigations:

- ▣ Stool: no occult blood

- ▣ C.T. scan of thorax, abdomen and pelvis:

 - Normal



Management

- ✚ Gynaecological Oncologist's opinion obtained from QMH:
 - ▣ Close observation required
 - ▣ No further intervention required at the time being
- ✚ Last follow-up:
 - ▣ 19-9-2001:
 - Vaginal examination: unremarkable
 - vault smear – inflammation changes only